



Perinatal Gazette

Newsletter of the Regional Perinatal Center
Westchester Medical Center



Volume 4, Issue 3

May 2003

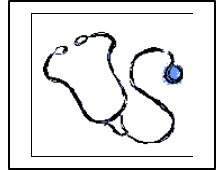
SPDS (Statewide Perinatal Database System) at Westchester Medical Center



On March 30th, WMC as the Regional Perinatal Center hosted the **NICU module** orientation given by the NYS Department of Health, for Good Samaritan, Hudson Valley, Our Lady Of Mercy, Sound Shore, St. John's, St. Luke's and Vassar hospitals. Over 20 participants were able to practice database entry during this hands-on session. This is an exciting step in our partnership with our affiliates toward fulfilling the mandated requirement that all babies admitted to a NICU/SCN be entered into the **SPDS NICU module**. As soon as the attendees have their HPN accounts and their infrastructure in place they can begin entering data. (Just a reminder to call **Pam Parker** at (315) 464-5706 or e-mail <mailto:parkerp@upstate.edu> when you are ready to begin entering.) Please call the SPDS team at WMC with any questions, concerns or problems. Over the next few weeks we will be calling to verify e-mail addresses, since this is often the mode of communication the DOH uses to notify us of any updates or changes and to address any issues your institution may have. Thanks to all who attended, we look forward to working together!

Donna Z. Dozor, R.N., M.S.
NICU Module Data Coordinator

When Is A Murmur "Innocent"? Guidelines For Referral To The Pediatric Cardiologist



Almost every child has an audible murmur at some time during his or her growing years.¹ Early diagnosis of pathologic murmurs is desirable to prevent consequences of mis-diagnosis, to identify diagnostic or treatment interventions and to reduce the risk of endocarditis. It is also important to identify functional murmurs to prevent unnecessary and expensive investigations and allay parental anxiety associated with the possibility of having "a child with heart disease". The evaluation of cardiac murmurs represents one of the most skilled and demanding aspects of the pediatric physical assessment. The decision for referral is based on the presumed diagnosis, confidence of the examiner, and level of parental anxiety.

A detailed physical examination and a critical evaluation of the murmur to rule out functional murmurs before ordering an echocardiogram is recommended by the 1997 American College of Cardiology/American Heart Association (ACC/AHA) Guidelines for the Clinical Application of Echocardiography^{2,3}. In these guidelines, innocent murmurs are defined as short systolic ejection murmurs that occur at the left sternal border, that are soft in intensity (grades 1 to 2/4), that are associated with a normal second heart sound, and do not have other cardiac examination abnormalities.

Innocent murmurs of childhood are either systolic or continuous. They are the "Still's" vibratory systolic murmur, pulmonary or aortic outflow murmur, physiologic peripheral pulmonary arterial stenosis murmur, supraclavicular systolic murmur, which are all systolic murmurs and the venous hum and mammary arterial soufflé (heard in adults), which are continuous murmurs. Innocent murmurs are never diastolic and are never associated with a palpable thrill. All murmurs are accentuated by fever, anemia, or increased cardiac output.

Still's Murmur: The most common innocent murmur in children is the vibratory systolic murmur that was described by Still in 1909. This murmur is most frequently heard between 2 and 6 years of age, but may be present in infancy as well as in older children. The murmur is vibratory, low pitched, early systolic, generally grade 1- 2, and heard best at the lower left sternal edge.

Continues on page 2

INSIDE THIS ISSUE

- 1 - **The Statewide Perinatal Database System**
When Is A Murmur "Innocent"?
- 2 - **Continued article on murmurs**
Happenings!
- 3 - **Mild Pyelectasis**
- 4 - **Save the Date for a Conference**

Continued from Murmurs

Physiologic Peripheral Pulmonary Arterial Stenosis (PPS) The most common murmur heard in newborns and infants is caused by PPS. These ejection systolic murmurs are long, soft and low pitched and widely heard over the axillae and back. They are usually present in normal neonates and infants. In young infants, the pulmonary trunk is relatively dilated and its branches are smaller and take off at sharp angles, accounting for the turbulence⁴. The PPS murmur is akin to the peripheral murmur of significant PA stenosis seen in Williams or rubella syndromes. These murmurs of significant stenoses are higher pitched and extend beyond the S2; and occur in older children, who may also have typical phenotypic features of the syndromes.

Outflow Murmurs: An innocent pulmonary outflow tract murmur may be heard in children as an early to mid-peaking ejection systolic murmur that is confined to the second and third interspace. The murmur is best heard in the supine position and is often heard with pectus excavatum; a straight back, or kyphoscoliosis, which results in approximation of the right ventricular outflow tract to the chest wall. The murmur of an atrial septal defect (ASD) is attributable to increased flow through the pulmonary outflow tract and may be mistaken for this murmur; however, the hyperdynamic right ventricular impulse, wide splitting of S2, and the presence of a mid-diastolic flow rumble are typical of an ASD. The murmur of pulmonary stenosis (PS) may be distinguished by the presence of a thrill, higher pitch, longer duration and a systolic ejection click (always pathologic). In PS, the S2 may be widely split, and P2 may be softer. Innocent systolic flow murmurs may also arise from the outflow tract in older children and adults during anxiety, anemia, hyperthyroidism, fever, or any other condition of increased systemic cardiac output. In athletes, slower heart rates with increased stroke volume may give rise to short low pitched murmurs. These murmurs must be distinguished from the systolic murmur left ventricular outflow tract obstruction. The presence of a family history for hypertrophic cardiomyopathy, history of unexplained death in a young individual justifies referral. Supraclavicular systolic murmurs are thought to arise from the major brachiocephalic vessels as they arise from the aorta.

Venous Hum: The most common type of continuous murmur (which may be grade 1-3) is the venous hum⁵. This murmur is heard just lateral to the sternocleidomastoid muscle and extends to the infraclavicular area. The murmur is generally louder on the right, with the patient sitting, and in diastole and elicited while turning away from the examiner. The murmur is decreased by gentle compression of the jugular vein or turning toward the side of the murmur. The murmur arises from turbulence at the neck veins.

Yi et al studied the cost-effectiveness of various strategies to evaluate heart murmurs in children and showed that tests such as X-rays or EKG did not add any specificity to diagnosing a murmur as pathologic⁶. Referring a patient with a murmur directly for an echocardiogram greatly increases the costs of patient care and such tests should be judiciously performed.

Continues top of page 2

Continued from Murmurs

It has also been shown that the current resolution of echocardiography can reveal details of cardiac function that may be physiologic but interpreted as pathologic, resulting in unnecessary testing or therapy as well as increased anxiety levels. Thus, in conclusion, every patient with a heart murmur should have a complete history and physical examination, keeping the above points in mind. Referral to a cardiologist may be indicated for any child with a variation of the above and in cases with a family history of heart disease or intense parental anxiety^{7,8}. Reassurance by the pediatrician prior to referral goes a long way in demystifying the cardiology visit.

REFERENCES

1. Danford DA, McNamara DG. Innocent murmurs and heart sounds. In: Garson AJ, Bricker JT, Fisher DJ, et al, eds. The science and practice of pediatric cardiology. 2nd ed. Baltimore: Williams and Wilkins; 1998. p. 2204.
2. ACC/AHA Task Force on Practice Guidelines, Committee on Clinical Application of Echocardiography. ACC/AHA Guidelines for the Clinical Application of Echocardiography. Circulation 1997;95:1686-744.
3. Cheitlin MD, Alpert JS, Armstrong WF, Aurigemma GP, Beller GA, Bierman FZ, et al. ACC/AHA guidelines for the clinical application of echocardiography: executive summary: a report of the American College of Cardiology/American Heart Association Task Force on practice guidelines (Committee on Clinical Application of Echocardiography). Developed in collaboration with the American Society of Echocardiography. J Am Coll Cardiol 1997;29 : 862-79.
4. Danilowicz DA, Rudolph AM, Hoffman JI, et al: Physiologic pressure differences between the main and branch pulmonary arteries in infants. Circulation 45:410-419, 1972
5. Cutforth R, Wiseman J, Sutherland RD: The genesis of the cervical venous hum. Am Heart J 80:488-492, 1970
6. Yi MS. Evaluation of heart murmurs in children: cost-effectiveness and practical implications. J Pediatr - 01-Oct-2002; 141(4): 504-11
7. Shry EA. Auscultation versus echocardiography in a healthy population with precordial murmur. Am J Cardiol - 15-Jun-2001; 87(12): 1428-30
8. Geggel RL Parental anxiety associated with referral of a child to a pediatric cardiologist for evaluation of a Still's murmur -J Pediatr- 01-Jun-2002; 140(6):747-52.

Usha Krishnan, M.D.

Assistant Professor of Pediatrics

Phone: (914) 594-4370

Email: usha.krishnan@nymc.edu

Happenings

San Pedro de Sula, Honduras. A team of physicians and nurses traveled to Honduras on a "Medical Brigade." Among the team of doctors and nurses were Neonatologist Lance A. Parton, M.D., from Westchester Medical Center, and Geneticist, Patricia A. Galvin-Parton, M.D., who was recently appointed Co-Director of the Division of Medical Genetics at Westchester Medical Center. Both are members of the Department of Pediatrics at New York Medical College. The team was lead by plastic surgeon Dr. Elliot Duboys, and Pediatric Anesthesiologist Dr. Walter Backus. The team triaged about 70 patients referred for a variety of conditions including cleft lip and palate, other congenital malformations, as well as burns and traumatic injuries. Surgeries were performed in collaboration with the father and son plastic surgeons from the Department of Surgery at the Dr. Mario Catarino Rivas Governmental Hospital-Drs. Andinos. The Partons received a guided tour of the Neonatal Intensive Care Unit of this hospital, from the Director of the Unit, Dr. Samuel Santos.

Mild Pyelectasis

Antenatal sonography readily demonstrates both normal and abnormal fetal urinary tract anatomy. Mild dilatation of the fetal renal pelvis (mild pyelectasis), usually observed during a second trimester "anatomy scan", is not an uncommon finding, and continues to be a challenge for prenatal and postnatal management.

Fetal kidneys continue to grow throughout gestation. Accordingly, the size of the renal pelvis increases as a function of gestational age. Various quantitative attempts have been made to distinguish between normal and abnormal renal pelvis size. Initial criteria utilized the ratio of renal pelvis diameter to renal diameter, with the normal range of 25-35%. Subsequently, a number of values for the upper limit of normal for the renal pelvis size have been reported, but the consensus has not been reached. Additional factors, such as differences in ultrasound equipment, sonographer's experience, filling and emptying states of the fetal bladder, intrarenal and extrarenal pelvices and type of target population contribute to the observed variation. Society for Fetal Urology recognizes mild fetal pyelectasis as a pelvocalyceal fluid-filled space with the shortest of two transverse perpendicular sonographic measurements of greater than or equal to 4mm and less than 10mm. Hydronephrosis is defined similarly, but with a measurement of greater than or equal to 10mm.

Significant controversy exists with respect to reported association of mild fetal pyelectasis with other urinary tract anomalies and chromosomal aneuploidy.

In the middle of 1980's, mild pyelectasis was described in association with fetal trisomy 13, 18 and 21. Initial reports demonstrated the presence of mild pyelectasis in up to 25% of fetuses with trisomy 21, and only in 2.8% of karyotypically normal fetuses. Generally, these reports, however, did not take into account other risk factors, such as maternal age and prior screening for Down syndrome. More recent studies showed that isolated finding of mild fetal pyelectasis in women younger than 36 years is associated with 0.33% risk of fetal aneuploidy, while in women over 36 years that risk increased to 2.22%. Attempts to incorporate the finding of mild pyelectasis, as a proposed "soft" marker, into antenatal programs for detection of aneuploidy, failed to increase significantly detection rate of fetuses affected with Down syndrome.

At present, there exists a relative paucity of data relating to the natural history of mild fetal pyelectasis from its detection in the second trimester to delivery as well as its association with other urinary tract abnormalities. Of note, mild fetal pyelectasis is more frequently reported as bilateral finding, with a significant male to female predominance: the observed incidence ratio in male to female fetuses is 2 : 1. The presence of maternal pyelectasis increases fivefold the likelihood of development of fetal pyelectasis. Most of the literature supports the view that the vast majority of cases of fetal pyelectasis detected in the second trimester will resolve either in the prenatal period or within one year after delivery. This tendency of prenatally detected pyelectasis to resolve spontaneously is supported by the normal postnatal renal appearance in up to 80% of cases followed up for one year after delivery. Unfortunately a study out of Boston

Continues top of page

Continued from Pyelectasis

Children's Hospital revealed that the incidence of residual reflux could be as high as 20% with any form of prenatal hydronephrosis surpassing the 1-2% rate in the general population.

Despite its relatively benign natural history, prenatally detected mild fetal pyelectasis can be of significance as an indicator of urinary tract pathologies, including uretero-pelvic junction obstruction, vesico-ureteral reflux, early signs of outflow obstruction, duplex systems upper tract dilatation in the absence of obstruction. The incidence and types of pathology reported varies considerably among authors, generally reflecting the differences in prenatal detection criteria and variability in postnatal investigations performed.

The size of the renal pelvis in the second trimester fetus with mild pyelectasis cannot be used to discriminate between obstructive and non-obstructive postnatal pathologies, and, therefore, cannot adequately predict those fetuses that will require surgical intervention after delivery. This necessitates a follow-up assessment in the third trimester, to identify those fetuses with mild second trimester pyelectasis, where dilatation of renal pelvis persists. The cut-off for the significantly increased anteroposterior diameter of the fetal renal pelvis in the third trimester is 10 mm. In a recent report, 4-50% of fetuses with pyelectasis identified in the second trimester, where dilatation progresses to more than 10 mm in the third trimester, required postnatal surgical correction.

Management of fetal pyelectasis detected in the second trimester should reflect upon its debatable association with aneuploidy and more established role as a predictor of urinary tract abnormalities. Second trimester detection of mild fetal pyelectasis should prompt a detailed ultrasound examination for extra-renal anomalies and other markers of aneuploidy. Invasive testing (amniocentesis) should be discussed based on consideration of other factors such as maternal age and any prior screening for Down syndrome. Careful examination of the urogenital tract should be performed to exclude other pathologies such as duplicated ureteral system or multicystic dysplastic kidney. The fetal urinary bladder should be carefully examined to ensure normal emptying and filling. Thickness of the bladder wall should be assessed and could be used as a marker for possible outflow obstruction. Prognosis cannot be accurately predicted after a single second trimester scan, but parents should be assured regarding benign natural course of mild fetal pyelectasis per se. A follow up ultrasound examination should be performed early in the third trimester. If pyelectasis has resolved by this time, it is debatable as to whether any further antenatal and postnatal investigations are warranted, as the risk of any clinically significant obstructive pathology is exceedingly small, but the risk of reflux does exist. If the renal pelvis dilatation persists, particularly if anteroposterior diameter is greater than 10mm, or if other pathology is suspected, a consultation with pediatric urologist is warranted. A joint pediatric urology – obstetrics conference can be helpful, as combined counseling of the patient may help to improve outcome and minimize anxiety. The full extent of necessary intervention should be fully assessed during postnatal investigation.

Continues on page 4

Continued from Pyelectasis

Reviewed by Dr. Israel Franco, Pediatric Urologist at Westchester Medical Center, Phone (914) 493-8628

References:

1. Adra AM, Mejides AA, Dennaoui MS, Betoum SN. 1995. Fetal Pyelectasis: is it always "physiologic"? Am J Obstet Gynecol 173:1263-1266.
2. Chitty LS, Chudleigh P, Pembrey M, Campbell S. 1999. Renal pathology in fetuses with mild pyelectasis: prediction of outcome. Ultrasound Obstet Gynecol 14(Suppl.1) :12.
3. Chudleigh T.2001. Mild pyelectasis. Prena diagn 21:936-941.

Aleksandr M. Fuks, M.D.
Fellow in Maternal and Fetal Medicine
Department of OB/GYN
WMC/NYMC
Phone: (914) 493-8398
Email: <mailto:aleksandr@wmc.com>

**Save the Date for a Conference:
Reproductive Health Issues
Of Women With Special Needs**

Explore how health, mental health and human service professionals can help women with mental illness and developmental disabilities to have healthier birth outcomes and healthier families.

June 3, 2003

Ramada Inn, Newburgh

\$40 includes continental breakfast and manual.

\$5 additional for CEUs.

Sponsored by Maternal-Infant Services Network

For more information, call MISN, (845) 928-7448

State Perinatal Database Team &

Perinatal Gazette Editorial Board

Edmund LaGamma, M.D., Director Newborn Medicine

(914) 493-8558 (edmund_lagama@nymc.edu)

Chaur- Dong (C.D.) Hsu, M.D., M.P.H., Director OB/GYN

(914) 347-1154 (mailto:chaur-dong_hsu@nymc.edu)

Heather L. Brumberg, M.D., M.P.H., Neonatal Epidemiologist

(914) 493-8491 mailto:heather_brumberg@nymc.edu

Susan Marchwinski, R.N., C., M.S., SPDS Coordinator

(914) 493-8590 (marchwinskisa@wcmc.com)

Donna Dozor, R.N., M.S. Neonatal Data Collection

(914) 493-8309 (dozord@wcmc.com)

Nancy Satou, R.N. Maternal Data Collection & Editor

(914) 493-8346 (satoun@wcmc.com)

We are interested in providing you with a newsletter that is relevant and of interest to you. Please contact us with perinatal topics you would like to see addressed.

For a copy of our newsletter or to be placed on our mailing list contact us by phone or e-mail.

Please see below the NYMC neonatal web site address to locate other issues of The Gazette:

<http://www.nymc.edu/neonatology>

Children's Hospital at Westchester Medical Center

95 Grasslands Road


Valhalla, New York 10595

Phone: 914-493-8590

Fax: 914-493-1493

E-mail: dozord@wcmc.com satoun@wcmc.com

marchwinskisa@wcmc.com



ADDRESS CORRECTION REQUESTED

